

Anosognosia for hemiparesis and hemiplegia: disturbed sense of agency and body ownership

Hans-Otto Karnath¹ & Bernhard Baier²

¹Section of Neuropsychology, Center of Neurology, Hertie-Institute for Clinical Brain Research, University of Tübingen, Tübingen, Germany

²Department of Neurology, University of Mainz, Mainz, Germany

Chapter for:
George P. Prigatano (ed.) *The Study of Anosognosia*. Oxford: Oxford University Press.

Address correspondence to:

Prof. Hans-Otto Karnath, MD PhD
Center of Neurology
University of Tübingen
Hoppe-Seyler-Str. 3
D-72076 Tübingen
Germany

Fax: ++49-7071-295957
E-mail: Karnath@uni-tuebingen.de

Introduction

Normally, we are aware that our arms and legs belong to us and not to someone else. When resting, we are aware that our limbs do not move, and when moving, we realize that our limbs cause the action. This natural knowledge is based on a self-awareness, a sense of being us. It allows us to discriminate between our own body and the bodies of other people, and to attribute an action to ourselves rather than to another person. One of the most challenging questions in cognitive sciences and in philosophy is how does this sense arise, how does it function, what mechanisms are involved? How can a subject determine the proper origin of an action or a body part? How is one able to attribute the agent of an action or a body part to one's self?

Recent studies addressed these questions experimentally by using different technical approaches. For example, behavioral investigations in healthy subjects studied the mechanisms underlying the rubber hand illusion (Botvinick & Cohen, 1998; Ehrsson, Spence, & Passingham, 2004; Ehrsson, Holmes, & Passingham, 2005; Ehrsson, Wiech, Weiskopf, Dolan, & Passingham, 2007; Tsakiris & Haggard, 2005; Moseley, Olthof, Venema, Don, Wijers, Gallace, & Spence, 2008). Watching a rubber hand being stroked synchronously with one's own (unseen) hand causes a phenomenal incorporation of the rubber hand; the rubber hand is experienced as part of one's own body. Studying the conditions evoking the illusion allows insights into the processes related to our feeling of body ownership. The sense of body ownership, as well as the awareness of being causally involved in an action – the sense of agency – have also been investigated by using functional neuroimaging methods (Farrer, Franck, Georgieff, Frith, Decety, & Jeannerod, 2003; Tsakiris, Hesse, Boy, Haggard, & Fink, 2007a). A further approach is the study of neurological patients showing specific disturbances of these senses after brain damage. Stroke patients with so-called "anosognosia for hemiparesis or for hemiplegia" (AHP) typically deny the weakness of their paretic or plegic limb(s) and are convinced that they move properly. Stroke patients may also show a "disturbed sense of ownership" (DSO) with respect to paretic/plegic limb(s). They experience their limb(s) as not belonging to them and may even attribute them to other persons.

The following chapter will give an overview of recent clinical and anatomical findings in patients with anosognosia for hemiparesis/-plegia. Interestingly, disturbed beliefs about the functioning of one's own limbs (the sense of agency) and disturbed

feelings of limb ownership (the sense of ownership) appear to be closely linked, both clinically and anatomically. It appears that the right insula may play a central role for both senses. We will argue that the right insula may be a central node of the network involved in human body scheme representation.

Anosognosia for hemiparesis/-plegia

Disturbed sense of agency

The characteristic feature of stroke patients with "anosognosia for hemiparesis/plegia (AHP)" is their false belief that they are not paralysed. Their feeling of being versus not being causally involved in an action – their sense of agency – is dramatically disturbed. Despite the very obvious fact that the contralesional arm, leg and/or face are plegic or severely paretic, these patients behave as if the disorder does not exist. Anton (1893) was the first to describe a patient, Wilhelm H., with a left-sided hemiparesis who did not recognize his weakness. Patients such as Wilhelm H. are convinced that their paretic/plegic limbs function normally. When asked to move the paretic/plegic arm or leg, they may do nothing or may move the limb of the opposite side. However, in both situations they are either convinced that they have successfully executed the task or may argue that they can move in a generic manner.

Some patients may even not experience their paresis/plegia when confronted with facts that unambiguously prove the disorder. For example, when asked to clap their hands, no sound is heard due to the paresis/plegia of one arm. Even under these conditions such patients are not able to correct their feeling of being involved in an action. Often, the patients comment on the apparent inability to move their arm or leg with confabulations such as "my leg is tired" or "my arm is lazy". When directly asked for the reason of not having moved the contralesional limb(s) such patients might respond: "I could walk at home, but not here. It's slippery here" (Nathanson, Bergman, & Gordon, 1952). Patients might argue that the arm "is too stiff, due to the cold" or that "somebody having a hold of the arm" (Nathanson et al., 1952) keeps the arm from moving.

Disturbed sense of ownership

In the normal experience of an action, the sense of agency and the sense of ownership coincide and are inseparable, though different sources generating these

senses have been assumed (Wolpert, 1997; Gallagher, 2000; Haggard, 2005; Tsakiris, Schütz-Bosbach, & Gallagher, 2007b). Therefore, it is interesting to know whether in neurological patients with brain damage a disturbed feeling of being causally involved in an action typically is associated or dissociated from a disturbed feeling of body ownership. Are both senses represented in common or rather separate neural systems?

Indeed, previous studies indicated that the false belief of not being paralyzed in patients with AHP may be associated with other abnormal attitudes towards and/or perceptions of the paretic/plegic limb(s) (Cutting, 1978; Stone, Halligan, & Greenwood, 1983; Feinberg, Roane, & Ali, 2000; Meador, Loring, Feinberg, Lee, & Nichols, 2000). Cutting (1978) referred to them as "anosognosic phenomena". Patients may experience their limb(s) as not belonging to them or as missing (asomatognosia), or may even attribute them to other persons (somatoparaphrenia). Both of these misbeliefs have a common characteristic, namely that the subjects experience a disturbed sense of ownership of their contralateral limb(s). They are convinced that this is not their own arm and/or leg. Thus, it has been suggested to unify these phenomena under the term "disturbed sensation of limb ownership" (DSO) (Figure 1; see also subsequent paragraphs). Other phenomena observed were "anosodiaphoria" (patients considering their paresis/plegia as harmless, i.e. are not appropriately concerned about it), "misoplegia" (patients expressing negative feelings about their paretic/plegic limbs), "personification" (patients giving names to their limbs), "kinaesthetic hallucinations", (the illusion that the paretic/plegic limb is moving as if controlled by an invisible force), or "supernumerary phantom limb" (patients' belief that a new, intact limb has appeared).

Although "anosognosic phenomena" and the false belief of not being paralyzed were regarded to be associated in some way (Feinberg et al., 2000), it is not clear how tight these phenomena are linked. Some studies found a strong association between a disturbed feeling of being involved in a limb movement and the experience that this limb is not belonging to the own body (Feinberg et al., 2000; Meador et al., 2000). Meador et al.'s data (2000) revealed an association close to 70% between the two phenomena in patients who underwent diagnostic intracarotid amobarbital inactivation of the right cerebral hemisphere. In contrast, Cutting (1978) observed that 29% of his patients with left hemiplegia showed such "anosognosic

phenomena” without having the false belief of not being paralyzed, while only 8% exhibited both phenomena.

A recent study re-assessed this issue in a large sample of 79 acute stroke patients with right brain damage and hemiparesis/-plegia (Baier & Karnath, 2008). The authors systematically examined both phenomena, the experience of being involved in an action, as well as the presence of various "anosognosic phenomena". Their particular focus was on the occurrence of a disturbed sensation of limb ownership (DSO). The authors found a false belief of not being paralyzed in about 15% of their patient sample. Interestingly, all but one (92%) of these patients also showed a disturbed sense of ownership (DSO) for their contralesional limb(s) (see Figure 1). No other subjects in the sample of 79 patients exhibited DSO. Baier and Karnath (2008) thus concluded that a disturbed sense of limb ownership obviously is a characteristic feature of AHP. If this surprising finding should be confirmed by future work, it would indicate that our sense of being involved in an action and our sense of ownership with respect to this limb not only are tightly linked phenomena in the normal experience of an action, but also in the case of their disturbance after brain injury.

-Figure 1 about here-

Two of the patients with DSO from the sample of Baier and Karnath (2008) attributed their limb to their wife, three to the examiner, and one to their room neighbour. Traditionally, such beliefs were termed "somatoparaphrenia". Five further patients with DSO from this sample neither attributed their limb to themselves nor to somebody else – traditionally labeled as "asomatognosia". Nevertheless, also the latter group of patients had the feeling that their limb somehow belonged to another person. When they were asked whether their limb belonged to another person, none of them clearly denied that it did not belong to somebody else. Answers were given such as "I don't know", or "I'm not sure", "I don't think so" etc. On the other hand, the patients with so-called "somatoparaphrenia" used terms like "perhaps" or "believe" when they attributed their limb to a specific person. This led the authors to suggest that these misbeliefs do not necessarily correspond to two distinct phenomena (Baier & Karnath, 2008). Rather, it seems that there is a continuum of conviction that the limb does not belong to one's own body but to someone else. "Disturbed sensation of

limb ownership (DSO)" thus appeared to be a more appropriate term to describe these feelings.

Normal or pathological? – criteria to assess the disturbed senses

Clinically, AHP and DSO are no trivial problems. A failure to realize a paresis of own extremities may delay medical consultation after a stroke (Ghika-Schmid, van Melle, Guex, & Bogousslavsky, 1999). Also, such patients are often reluctant to enroll in rehabilitation programs (Hartman-Maeir, Soroker, & Katz, 2001; Appelros, Karlsson, Seiger, & Nydevik, 2002). Thus, a reliable diagnosis of the disorder as soon as possible after onset is desired.

However, to date some inconsistencies in diagnosing the misbeliefs still seem to exist between different investigators. Consequently, widely varying incidence rates have been reported for AHP in acute stroke patients, ranging from 7 to 77% (for review Orfei, Robinson, Prigatano, Starkstein, Rüschi, Bria, Caltagirone, & Spalletta, 2007). This variation points to a central question: What exactly do we mean when we talk about "anosognosia for hemiparesis/-plegia"? Shall we already consider a patient as "anosognosic" if he/she does not spontaneously mention the deficit in a conversation with the examiner? Indeed, according to Bisiach et al.'s anosognosia scale (1986) patients should be considered to have "mild anosognosia" when they do not acknowledge their hemiparesis spontaneously following a general question about their complaints. However, the question arises whether there are "normal", i.e. non-pathological, explanations for not addressing a deficit after such a general question?

A recent study investigated this question (Baier & Karnath, 2005). The authors examined 128 acute stroke patients for AHP by applying the anosognosia scale of Bisiach et al. (1986). They closely analyzed the motives and the explanations given by those patients who did not acknowledge their hemiparesis spontaneously, i.e. who traditionally would have been diagnosed showing at least "mild AHP". The authors detected that 94% of these patients suffered from other neurological deficits in addition to their paresis/plegia. Following a general question about their complaints they mentioned these deficits instead of limb paresis/plegia. However, the same patients immediately acknowledged their paresis/plegia when the examiner addressed the strength of their limbs. Baier and Karnath (2005) thus concluded that a reason for not mentioning a paresis/plegia after a first, general question could be that

other, additional deficits have a higher impact for these subjects after stroke. The authors argued that such behavior is reasonable and thus should not be diagnosed as "anosognosia". With respect to the anosognosia scale of Bisiach et al. (1986), they suggested that only patients with grade 2 (the disorder is acknowledged only after demonstrations through routine techniques of neurological examination) and grade 3 (no acknowledgement of the disorder can be obtained) should be labeled as "AHP" (see Table 1). If this criterion is used, comparable incidence rates between 10 and 18% are observed for AHP in unselected samples of acute, hemiparetic stroke patients (Starkstein, Fedoroff, Price, Leiguarda, & Robinson, 1992; Appelros, Karlsson, Seiger, & Nydevik, 2002; Baier & Karnath, 2005; Baier & Karnath, 2008).

Since patients with a disturbed sense about the functioning of body parts often exhibit additional disturbance of sensing limb ownership (DSO), a clinical exam of stroke patients with hemiparesis/-plegia should combine both aspects (see Tables 1 and 2). Beyond these aspects, the questionnaire illustrated in Table 2 also explores whether a subject has a lack of appropriate concern of the paretic/plegic limbs (*anosodiaphoria*); expresses negative feelings, e.g. hatred, for his/her limb (*misoplegia*); gives his/her limbs names (*personification*); feels his/her limbs moving automatically (*kinesthetic hallucinations*); or is convinced that a new, intact limb has appeared (*supernumerary phantom limb*).

-Tables 1 and 2 about here-

Pathogenetic models

The pathogenesis of AHP continues to be a subject of controversy. Early investigators like Anton (1893) and Babinski (1914) emphasized the importance of hemisensory loss, particularly the loss of proprioception for the genesis of the disorder. The loss of sensory feedback would induce the patients' unawareness of the contralateral limb function. Levine, Calvanio, & Rinn (1991) postulated that in the absence of somatosensory and proprioceptive input, the patient does not have immediate knowledge that his/her limb has moved or not moved but rather must discover his paresis/plegia by observing his failure in tasks requiring movement of the affected limb. General intellectual impairment or spatial neglect might prevent this discovery. Other models considered AHP as a defect of neural awareness systems

(McGlynn & Schacter, 1989), an overestimation of self-performance, lack of mental flexibility, inability to integrate episodic awareness into generic knowledge (Marcel, Tegnér, & Nimmo-Smith, 2004), or a psychological defense mechanism manifesting "the patient's drive to be well" when he/she is facing a sudden and threatening reality such as hemiparesis/-plegia after stroke (Weinstein & Kahn, 1950). Carruthers (2008) claimed that patients with AHP might have an impaired "online" representation of their body (what the body is currently like) due to a lack of access to an updated "offline" representation of the body (the state of what the body is usually like). New information from the body has not been integrated since the patient was paralyzed. The patients' access to the erroneous "offline" representation makes them feel embodied as they were before the paresis.

Several authors have focused on processes involved in motor planning and motor control to explain the disorder. According to the Feed-Forward model suggested by Heilman (1991), weakness of a limb is recognized when a mismatch is detected between an intended movement and the actual motor performance. A module comparing intended and observed movements notes possible discrepancies. Patients with AHP do not intend to move. As a consequence, no mismatch is generated in the comparator module and the patient does not recognize his/her paresis. Berti and Pia (2006) proposed a modification of this hypothesis, suggesting that in AHP the comparator module itself is deficient. A further model by Frith, Blakemore, & Wolpert (2000) assumed that awareness of the current and possible states of the motor system are based on sensory information from the muscles, the skin, and the motor command stream. Awareness of initiating a movement is based on a representation of the predicted consequences of making that movement. In patients with AHP, the representations of the desired and the predicted positions of the limb are intact, inducing the normal experience of initiating a movement. However, according to Frith and colleagues, these patients are not aware of the actual limb position. Due to a loss of sensory feedback (by damage of the relevant brain regions or by spatial neglect), information about the actual position of the limb indicating that no motor action has occurred is not available. AHP thus is assumed to result from the lack of experiencing a discrepancy between intended and predicted positions, based on the unawareness of the actual state of the limb. As a result, a successful motor action is pretended and a false experience of movement is induced. A first direct experimental investigation of this hypothesis has recently been

undertaken by Fotopoulou, Tsakiris, Haggard, Vagopoulou, Rudd, & Kopelman (2008).

Anatomy of AHP – the neural correlates of disturbed experience of one's own limbs and actions

Disturbed sense of agency

The neural correlates of the patient's false belief of not being paralyzed despite obvious hemiparesis/-plegia is also a matter of considerable debate. Lesions of various brain areas such as parietal, temporal and frontal cortex, the thalamus, corona radiata, basal ganglia, internal capsule, and pons were suggested to evoke AHP (Bisiach et al., 1986; Levine et al., 1991; Starkstein et al., 1992; Ellis & Small, 1997; Maeshima, Dohi, Funahashi, Nakai, Itakura, & Komai, 1997; Bakchine, Crassard, & Seilhan, 1997; Evyapan & Kumral, 1999). Consistently, several studies have observed large lesions in the territory of the middle cerebral artery of the non-dominant hemisphere to be associated with the disorder. Bisiach and co-workers (1986) assumed that large lesions encompassing the right infero-posterior parietal regions as well as the right thalamus and/or the lenticular nucleus lead to a disturbed feeling of being causally involved in an action. Another group study compared 30 acute stroke patients with AHP and ten patients with hemiplegia and spatial neglect but no AHP (Ellis & Small, 1997). The patients with AHP had right-sided lesions, in particular in the deep white matter, the basal ganglia, the thalamus and insula, whereas both patient groups had lesions of frontal areas, especially the premotor, Rolandic and paraventricular regions. The authors concluded that AHP is due to damage of neuronal circuits involving the basal ganglia, leading to an inflexibility of the response to the lack of movement in a paretic/plegic limb. A recent review of 23 single case and group studies revealed that among the 83 reported patients with AHP, 44 patients had lesions of the frontal lobe and/or the parietal lobe, 31 patients of the temporal lobe and 12 patients of the occipital lobe (Pia, Neppi-Modona, Ricci, & Berti, 2004). Only 17 patients were reported with a lesion restricted to a single cortical area, whereas in 45 cases more than one cortical lobe was involved. With regard to subcortical structures 34 out of the 83 patients with AHP had subcortical lesions. The basal ganglia (22 patients), the insula (19 patients), and the internal capsule (18 patients) were the most frequently affected subcortical structures.

Recently, new tools have been developed that allow more precise lesion localization in humans (for a review see Rorden & Karnath, 2004). These techniques reduce significantly the uncertainty brought in by the procedures used in previous anatomical studies where only rough anatomical landmarks could be taken into consideration, where lesion documentation still was based on a paper-and-pencil basis, where only a rather small number of patients was included, and no direct visual and/or statistical comparisons between patients with and without a disturbed sense of agency was carried out. In contrast, the new techniques can use the entire lesioned area of each individual subject for a high resolution analysis (Rorden & Karnath, 2004). Different procedures have been developed that allow voxelwise statistical comparisons between anatomical groups. Such voxelwise lesion-behavior mapping (VLBM) techniques differ in major respects but share the idea of comparing the performance of individuals with injury to a voxel to the performance of individuals where that voxel is not injured (Rorden, Karnath, & Bonilha, 2007; Rorden, Fridriksson, & Karnath, 2009). VLBM techniques detect brain regions that predict poor performance when injured and good performance when spared (see Box 1).

-Box 1 about here-

Based on such new analysis techniques, four recent studies compared the location of brain lesions in patients with and without AHP (Berti, Bottini, Gandola, Pia, Smania, Stracciari, Castiglioni, Vallar, & Paulesu, 2005; Karnath, Baier, & Nägele, 2005; Baier & Karnath, 2008; Vocat & Vuilleumier, this volume). Karnath and colleagues (2005) investigated 14 consecutively admitted acute stroke patients with right brain damage who showed the false belief that they are not paralysed. Twelve of these patients showed left-sided plegia and in 2 patients the left-sided limb(s) were severely paretic. The motor defect thus was homogeneously represented in this group: the majority of the sample (86%) demonstrated complete absence of movement (plegia). Since many of the patients with AHP had additional neurological defects such as spatial neglect, extinction, etc., the control group had to be selected such that all neurological defects were present with the same frequency and severity, except for the critical variable to be investigated: the false belief of not being paralyzed. The authors thus compared the AHP patients with a group of 13 right brain damaged acute stroke patients admitted in the same period who had no AHP

but who were comparable with respect to age, acuity of lesion, size of lesion, strength of hemiparesis/-plegia, the frequency of sensory loss, and the frequency of additional spatial neglect, extinction, and visual field defects. Lesion analysis between the groups revealed that the right posterior insula was commonly damaged in patients showing the false belief about the functioning of own limbs but was significantly less affected in patients without that disorder (see Figure 2A). Thus, the authors speculated that the right insular cortex might be a crucial anatomical region in integrating input signals related to self-awareness about the functioning of body parts.

-Figure 2 about here-

A study by Berti and colleagues (2005) also examined 30 patients with right-sided brain lesions and contralateral hemiplegia. The superimposed lesion plots of seventeen patients with AHP and neglect were compared to 12 patients with neglect but without AHP. Their findings revealed that AHP was associated with lesions affecting the dorsal premotor cortex (Brodmann's area (BA) 6) and BA 44, motor area BA 4, somatosensory cortex, BA 46 as well as the insula. The authors concluded that, in particular, premotor areas 6 and 44, motor area 4, and the somatosensory cortex are part of a system relevant for motor control as well as self-awareness of motor actions. In our opinion the main difference between their findings and those obtained by Karnath and co-workers (2005) is that Berti et al. (2005) used a very specific selection of subjects for their control group. The control subjects, i.e. the patients with spatial neglect but without AHP, had mainly lesions of subcortical structures such as the basal ganglia, thalamus, and periventricular white matter (Berti et al., 2005; their Figure 1B). However, more frequently spatial neglect is associated with cortical lesions, involving parietal, temporal and/or frontal regions (Heilman, Watson, Valenstein, & Damasio, 1983; Vallar & Perani, 1986; Husain & Kennard, 1996; Karnath, Ferber, & Himmelbach, 2001; Karnath, Fruhmann Berger, Küker, & Rorden, 2004; Buxbaum, Ferraro, Veramonti, Farne, Whyte, Ladavas, Frassinetti, & Coslett, 2004; Committeri, Pitzalis, Galati, Patria, Pelle, Sabatini, Castriota-Scanderbeg, Piccardi, Guariglia, & Pizzamiglio, 2007). A neglect control group in which the cortical lesion sites associated with spatial neglect are underrepresented, controls only for the subcortical sites of spatial neglect. When such a group is used

as a control for a group of patients suffering from both AHP and spatial neglect, the resulting lesion contrast map does not only reveal brain areas related to AHP. In addition, the contrast map shows also those areas that are linked (at the cortical level) with spatial neglect. Part of the cortical brain regions revealed by Berti and colleagues (2005) thus most likely represent neural correlates of spatial neglect rather than of AHP.

Evidence supporting the hypothesis that the right insular cortex might be a crucial anatomical region in integrating input signals related to self-awareness about the functioning of body parts (Karnath et al., 2005) has been reported from two further studies investigating lesion localization in AHP. The first study examined a series of 79 acute stroke patients with right brain damage and hemiparesis/-plegia showing AHP versus not showing AHP (Baier & Karnath, 2008). In correspondence with their earlier findings, in this new patient sample the authors found that the brain area more frequently affected in AHP patients compared to controls was the right insular cortex (Figure 2B; for details see subsequent paragraph). The second study analysed the structural damage of patients with AHP in relation to their anosognosia scores collected 3 days after the stroke and a second assessment one week later (Vocat & Vuilleumier, this volume). In both phases, the authors found the most distinctive lesion areas in the right insular cortex and adjacent anterior subcortical structures. One week post-stroke, additional regions were observed in the right hemisphere. They included the parieto-temporal junction, premotor areas, and the amygdalo-hippocampal complex. The authors interpret these sites as constituents of a network of interacting cerebral regions involved in the occurrence and persistence of AHP.

Disturbed sense of ownership

The studies of Karnath et al. (2005), Berti et al. (2005), as well as Vocat and Vuilleumier (this volume) concentrated on the phenomenon of a disturbed feeling of being causally involved in an action – the sense of agency. Whether or not the patients included in these investigations also experienced their paretic/plegic limb(s) as not belonging to them, i.e. whether or not they had a disturbed feeling of body ownership (DSO), was not reported. A recent study addressed this issue, examining the neural correlate of a disturbed feeling of limb ownership (Baier & Karnath, 2008). The authors investigated a series of 78 subjects with acute right hemisphere stroke

and left-sided hemiparesis/-plegia. They found a "disturbed sensation of ownership" (DSO) for the paretic/plegic limb(s) in 11 subjects, i.e. in 14% of their patient sample. Interestingly, all 11 patients suffered from a false belief of not being paralysed, i.e. also showed a disturbed sense of agency. The brain lesions of these patients were contrasted to those of 11 acute right hemisphere stroke patients without such disorder but who were comparable with respect to age, acuity of lesion, size of lesion, strength of hemiparesis/-plegia, and the frequency of additional spatial neglect and visual field defects. Lesion analysis between the groups revealed that the right posterior insula was more frequently affected in patients showing a disturbed experience of own limbs and actions (see Figure 2B). The data suggested a tight anatomical relationship between the two phenomena. The authors concluded that the right insula might be involved not only in the genesis of one's belief about limb movement, but also in our sense of limb ownership.

Right insula for our sense of limb ownership and self-awareness of actions

The Island of Reil or the insular cortex is the cortical tissue beneath the frontal and temporal lobe which consists of four to seven oblique gyri encircled by the insular sulcus (Mesulam & Mufson, 1985; Duvernoy, 1991; Augustine, 1996; Türe, Yaşargil, Al-Mefty, & Yaşargil, 1999; Naidich, Kang, Fatterpekar, Delman, Gultekin, Wolfe, Ortiz, Yousry, Weismann, & Yousry, 2004; Rhoton, 2007). The central sulcus of the insula divides the insular cortex into a large anterior part and a posterior part (Naidich et al., 2004). The anterior part is divided by several shallow sulci into three to five short gyri whereas the posterior insular cortex is formed by the anterior and the posterior long gyri. While the anterior part has more extensive connections with limbic, paralimbic, olfactory, gustatory and autonomic structures, the major projections of the posterior insula include those with the primary and secondary somatosensory area (SI, SII), the superior and inferior temporal and parietal cortices, orbitofrontal, prefrontal, and premotor cortex, auditory cortex (AI, AII), amygdala, thalamus, basal ganglia, and the cingulate gyrus (Mesulam & Mufson, 1985; Augustine, 1996; Flynn, Benson, & Ardila, 1999).

Converging evidence has been reported that the anterior insular cortex is a central structure for pain mechanisms and temperature regulation (Craig, Reiman,

Evans, & Bushnell, 1996; Craig, Chen, Bandy, & Reiman, 2000; Brooks, Nurmikko, Bimson, Singh, & Roberts, 2002; Maihöfner, Kaltenhäuser, Neundörfer, & Lang, 2002; Frot & Maugière, 2003; Schreckenberger, Siessmeier, Viertmann, Landvogt, Buchholz, Rolke, Treede, Bartenstein, & Birklein, 2005; Kong, White, Kwong, Vangel, Rosman, Gracely, & Gollub, 2006). This led to the view that this cortical area might represent an important correlate of human “interoception” (Craig, 2002, 2009). Other interoceptive stimuli that have been shown to be associated with the anterior insula were, for example, taste perception (Faurion, Cerf, Le Bihan, & Pillias, 1998; Ogawa, Wakita, Hasegawa, Kobayakawa, Sakai, Hirai, Yamashita, & Saito, 2007), thirst (Farrell, Egan, Zamarripa, Shade, Blair-West, Fox, & Denton, 2006), and autonomic functions such as blood pressure regulation (Kimmerly, O'Leary, Menon, Gati, & Shoemaker, 2005), visceral motor functions (Humbert & Robbins, 2007), and bladder control (Griffiths, Tadic, Schaefer, & Resnick, 2007). Moreover, the anterior insular cortex was suggested to be involved in emotional feelings such as anger or anxiety (Phillips, Young, Senior, Brammer, Andrew, Calder, Bullmore, Perrett, Rowland, Williams, Gray, & David, 1997; Damasio, Grabowski, Bechara, Damasio, Ponto, Parvizi, & Hichwa, 2000; Paulus & Stein, 2006; Stein, Simmons, Feinstein, & Paulus, 2007; Ehrsson et al., 2007), in craving (Contreras, Ceric, & Torrealba, 2007; Naqvi, Rudrauf, Damasio, & Bechara, 2007), and in visual self-recognition (Devue, Collette, Balteau, Degueldre, Luxen, Maquet, & Brédart, 2007).

It has been suggested that the posterior insular cortex might represent a somatosensory association area (Mesulam & Mufson, 1985; Augustine, 1996). Neurons in this area showed responsiveness to auditory and to somatosensory stimulation, the latter with large receptive fields covering the limbs, trunk, or entire body (Schneider, Friedman, & Mishkin, 1993). Several investigators also reported a link of the posterior insula to motor processes. In patients with an insular tumor (Fiol, Leppick, Mireles, & Maxwell, 1988) or an aneurysm laying on the insula (Schneider, Calhoun, & Kooi, 1971), an epileptic aura consisting of rotational and circling limb movements was reported. Early stimulation experiments at the posterior insula reported that gross movements (Showers & Lauer, 1961) as well as restricted movements of single muscles or small groups of muscles could be elicited (Sugar, Chusid, & French, 1948). However, these latter findings lack confirmation using more recent neurophysiological techniques. Lesion and functional imaging studies in humans further suggested that the posterior insula may be part of the human

vestibular system (Brandt, Dieterich, & Danek, 1994; Bense, Bartenstein, Lochmann, Schlindwein, Brandt, & Dieterich, 2004; Dieterich & Brandt, 2008), and might be involved in language and articulation processes in the left hemisphere (Dronkers, 1996; Cereda, Ghika, Maeder, & Bogousslavsky, 2002), as well as in processes of spatial exploration and orientation in the right hemisphere (Karnath et al., 2004).

The recent findings (see above) deriving from lesion localization in patients with AHP and DSO suggest that the right insular cortex may also play a crucial role in the genesis of our sense of limb ownership and our self-awareness of limb movement (Karnath et al., 2005; Baier & Karnath, 2008). This hypothesis is supported by other observations. For example, Cereda and colleagues (2002) documented that even a small, isolated lesion of the right insula suffices to induce a disturbed feeling of limb ownership (DSO). They screened a total of 4800 stroke patients from the Lausanne Stroke Registry to identify patients showing a lesion restricted to only the insular cortex. They found four patients and identified five characteristic clinical disturbances of insular strokes: (1) somatosensory deficits with contralateral pseudothalamic sensory stroke in three patients; (2) taste disorder in a patient with a left posterior insular infarct; (3) pseudovestibular syndrome in three patients with posterior insular infarct; (4) cardiac disturbance with hypertensive disorder in one patient with right posterior insular infarct and (5) neuropsychological disorders including aphasia (left posterior insular infarct) and –interesting in the present context– one patient with damage to the insular cortex who showed disturbed sensation of limb ownership (DSO). This latter patient was one of the two patients with a right-sided insular infarct identified by Cereda and colleagues (2002). The 75-year-old right-handed woman was hospitalized after she woke up in the night with a sensation of being touched by a stranger's hand and alarmed by a foreign body in her bed, not recognizing her own left upper limb.

Further evidence that the right insula is involved in our feeling of body ownership and our self-awareness of limb movement comes from studies using caloric vestibular stimulation. PET imaging has revealed that vestibular stimulation induces activation predominantly of the right posterior insula as well as the right temporoparietal junction, SI and SII, retroinsular cortex, putamen, and anterior cingulate cortex (Bottini, Sterzi, Paulesu, Vallar, Cappa, Erminio, Passingham, Frith, & Frackowiak, 1994; Bottini, Karnath, Vallar, Sterzi, Frith, Frackowiak, & Paulesu, 2001; Emri, Kisely, Lengyel, Balkay, Márián, Mikó, Berényi, Sziklai, Trón, & Tóth,

2003). Therefore, it is interesting that such stimulation in patients with right brain damage may induce transitory remission of anosognosia for hemiparesis/-plegia and of DSO (Cappa, Sterzi, Vallar, & Bisiach, 1987; Bisiach, Rusconi, & Vallar, 1991; Rode, Charles, Perenin, Vighetto, Trillet, & Aimard, 1992; Vallar, Bottini, & Sterzi, 2003).

Spinazzola and colleagues (2008) investigated four right brain damaged patients showing anosognosia for hemianaesthesia. Interestingly, all four subjects presented a lesion including the right insular cortex. This suggests that not only processes linked with AHP but also with anosognosia for hemianaesthesia appear to be associated with the right insula.

Supporting evidence for the role of the right posterior insula for self-awareness of limb actions also comes from recent positron emission tomography (PET) experiments (Farrer et al., 2003; Farrer, Franck, Frith, Decety, Georgieff, d'Amato, & Jeannerod, 2004; Tsakiris et al., 2007a). Farrer et al. (2003) found involvement of the right posterior insula when subjects had to indicate whether movements they saw corresponded to their own executed movements or were controlled by someone else. The authors observed a gradually reduced activity of the right posterior insula with an associated gradual decreased feeling of controlling a movement. The level of activity in the right posterior insula correlated with the experience of controlling an action. Right insular activity was high when the subjects experienced a concordant feeling between the viewed and the actually executed movement. Another PET-study by the same group showed that in patients with schizophrenia the subjects' degree of movement control was related to regional cerebral blood flow in the right angular gyrus but not in the insular cortex (Farrer et al., 2004). The authors argued that the differences in activation between normal subjects (Farrer et al., 2003) and patients with schizophrenia (Farrer et al., 2004) might reflect the impaired recognition of own actions in patients with schizophrenia.

A recent fMRI study explored the mechanisms of disembodiment (Corradi-Dell'Acqua, Ueno, Ogawa, Cheng, Rumiata, & Iriki, 2008). The authors presented a movie in which three fictional players were throwing each other a ball. The subjects' key-press could either be synchronous or asynchronous with one of the players' actions. The study revealed that the left posterior insular cortex was activated when the movements of the subjects were synchronous with those of the players in the video game. The finding could suggest that not only the right but also the left insula is

involved in mechanisms differentiating between one's own body and the external environment.

An experimental paradigm that allows manipulation of the feeling of body ownership is the rubber hand illusion (Botvinick & Cohen, 1998; Botvinick, 2004). Studies have found that the observation of a rubber hand being stroked synchronously with one's own hidden hand can cause the rubber hand to be attributed to one's own body (see Figure 3). This paradigm was applied in a recent PET study (Tsakiris et al., 2007a). Healthy subjects saw either a right or a left rubber hand being touched either synchronously or asynchronously with respect to their own hidden right hand. Across all conditions, participants judged the felt position of their own hand before and after visuotactile stimulation. The proprioceptive judgment was used as a behavioral measure of the phenomenal incorporation of the rubber hand into one's own body. The authors found that the elicited feeling of ownership for the rubber hand was positively correlated to activity in the right posterior insula and the right frontal operculum. Conversely, when the rubber hand was not attributed to the self, activity was observed in the contralateral parietal cortex, particularly the somatosensory cortex. Tsakiris and colleagues concluded that the posterior insula is active even in the absence of movement and efferent information, i.e. when a non-acting subject integrates multisensory information to decide if a body part belongs to the own body. Based on this finding they proposed that the posterior insula incorporates the sense of body ownership *per se*.

-Figure 3 about here-

Craig has argued that the sense of the physiological condition of the body, i.e. the "interoception" (see above), which is associated with autonomic control, is engendered in the right anterior insula and might present the basis for our awareness of the "feeling self" (Craig, 2002, 2009). He suggested that this area might represent a polymodal integration zone involved in all human feelings and thus may contain a representation of 'me' as a feeling entity, engendering the fundamental phenomenon of human subjective awareness (Craig, this volume). Evidence for this view comes from the various observations that the insula is involved in pain mechanisms, temperature regulation, in subjective feelings such as anger or anxiety, or in autonomic regulation processes (for a more detailed review, see Craig, 2009). Direct

evidence that the interoceptive systems implemented in the insular cortex are associated with the sense of body ownership has come from two recent studies using the rubber hand illusion paradigm. Moseley and colleagues (2008) found that the sense of body ownership and the autonomic regulation of the body are tightly linked. They observed that the feeling of ownership for a rubber hand was associated with a decrease of the skin temperature of the real hand. This effect was limb-specific, i.e. a decrease of skin temperature only occurred in the aligned, hidden real hand. Ehrsson and colleagues (2007) showed that threat to the rubber hand can induce a similar level of activity in the brain areas associated with anxiety and interoceptive awareness, i.e. anterior insular and anterior cingulate cortex, as when the person's real hand is threatened. Their findings thus suggest that incorporated artificial limbs can evoke the same feelings as real limbs. It appears as if indeed our sense of body ownership is tightly linked with the insular interoceptive systems.

Conclusions

In the normal experience of an action, the sense of agency and the sense of ownership coincide. Recent findings have suggested that these two feelings are closely linked in brain damaged patients as well. In stroke patients with AHP, a disturbed feeling of being causally involved in an action often seems to be associated with a disturbed feeling of body ownership. Also, both senses seem to share common neural structures. New lesion mapping and analysis methods revealed that the false belief about the functioning of own limbs as well as a disturbed sensation of ownership with respect to these limbs are associated with damage involving particularly the right insula. Functional brain imaging studies supported the role of the right posterior insular cortex in self-awareness of actions and in our sense of limb ownership. Thus, it seems as if the right insula plays a central role for both senses, our sense of limb ownership as well as our sense of agency. The insular cortex is characterised by an extensive spectrum of cortical and subcortical somatosensory and motor connections. The right posterior insula thus may constitute a central node of the network involved in human body scheme representation.

References

Anton, G. (1893). Beiträge zur klinischen Beurtheilung und zur Localisation der Muskelsinnstörungen im Grosshirne. *Zeitschrift für Heilkunde*, 14, 313-348.

Appelros, P., Karlsson, G. M., Seiger, A., & Nydevik, I. (2002). Neglect and anosognosia after first-ever stroke: incidence and relationship to disability. *Journal of Rehabilitation Medicine*, 34, 215-220.

Augustine, J. R. (1996). Circuitry and functional aspects of the insular lobe in primates including humans. *Brain Research Reviews*, 22, 229-244.

Babinski, J. (1914). Contribution à l'étude des troubles mentaux dans l'hémiplégie organique cérébrale (anosognosie). *Revue Neurologique*, 27, 845-848.

Baier, B., & Karnath, H.-O. (2005). Incidence and diagnosis of anosognosia for hemiparesis. *Journal of Neurology, Neurosurgery, and Psychiatry*, 76, 358-361.

Baier, B., & Karnath, H.-O. (2008). Tight link between our sense of limb ownership and self-awareness of actions. *Stroke*, 39, 486-488.

Bakchine, S., Crassard, I., & Seilhan, D. (1997). Anosognosia for hemiplegia after a brainstem haematoma. A pathological case. *Journal of Neurology, Neurosurgery, and Psychiatry*, 63, 686-687.

Bense, S., Bartenstein, P., Lochmann, M., Schlindwein, P., Brandt, T., & Dieterich, M. (2004). Metabolic changes in vestibular and visual cortices in acute vestibular neuritis. *Annals of Neurology*, 56, 624-630.

Berti, A., & Pia, L. (2006). Understanding motor awareness through normal and pathological behavior. *Current Directions in Psychological Science*, 15, 245-250.

Berti, A., Bottini, G., Gandola, M., Pia, L., Smania, N., Stracciari, A., Castiglioni, I., Vallar, G., & Paulesu, E. (2005). Shared cortical anatomy for motor awareness and motor control. *Science*, *309*, 488-491.

Bisiach, E., Vallar, G., Perani, D., Papagno, C., & Berti, A. (1986). Unawareness of disease following lesions of the right hemisphere: anosognosia for hemiplegia and anosognosia for hemianopia. *Neuropsychologia*, *24*, 471-482.

Bisiach, E., Rusconi, M. L., & Vallar, G. (1991). Remission of somatoparaphrenic delusion through vestibular stimulation. *Neuropsychologia* *29*, 1029-1031.

Brandt, T., Dieterich, M., & Danek, A. (1994). Vestibular cortex lesions affect the perception of verticality. *Annals of Neurology*, *35*, 403-412.

Brooks, J. C, Nurmikko, T. J, Bimson, W. E., Singh, K. D., & Roberts, N. (2002). fMRI of thermal pain: effects of stimulus laterality and attention. *Neuroimage*, *15*, 293-301.

Bottini, G., Sterzi, R., Paulesu, E., Vallar, G., Cappa, S. F., Erminio, F., Passingham, R. E., Frith, C. D., & Frackowiak, R. S. (1994). Identification of the central vestibular projections in man: a positron emission tomography activation study. *Experimental Brain Research*, *99*, 164-169.

Bottini, G., Karnath, H.-O., Vallar, G., Sterzi, R., Frith, C. D., Frackowiak, R. S., & Paulesu, E. (2001). Cerebral representations for egocentric space: functional-anatomical evidence from caloric vestibular stimulation and neck vibration. *Brain*, *124*, 1182-1196.

Botvinick, M. (2004). Probing the neural basis of body ownership. *Science*, *305*, 782-783.

Botvinick, M., & Cohen, J. (1998). Rubber hands “feel” touch that eyes see. *Nature*, *391*, 756.

Buxbaum, L. J., Ferraro, M. K., Veramonti, T., Farne, A., Whyte, J., Ladavas, E., Frassinetti, F., & Coslett, H. B. (2004). Hemispatial neglect: subtypes, neuroanatomy and disability. *Neurology*, *62*, 749-756.

Cappa, S., Sterzi, R., Vallar, G., & Bisiach, E. (1987). Remission of hemineglect and anosognosia during vestibular stimulation. *Neuropsychologia*, *25*, 775-783.

Carruthers, G. (2008). Types of body representation and the sense of embodiment. *Consciousness and Cognition*, *17*, 1302-1316.

Cereda, C., Ghika, J., Maeder, P., & Bogousslavsky, J. (2002). Strokes restricted to the insular cortex. *Neurology*, *59*, 1950-1955.

Committeri, G., Pitzalis, S., Galati, G., Patria, F., Pelle, G., Sabatini, U., Castriota-Scanderbeg, A., Piccardi, L., Guariglia, C., & Pizzamiglio, L. (2007). Neural base of personal and extrapersonal neglect in humans. *Brain*, *130*, 431-441.

Contreras, M., Ceric, F., & Torrealba, F. (2007). Inactivation of the interoceptive insula disrupts drug craving and malaise induced by lithium. *Science*, *318*, 655-658.

Corradi-Dell'Acqua, C., Ueno, K., Ogawa, A., Cheng, K., Rumiata, R. I., & Iriki, A. (2008). Effects of shifting perspective of the self: an fMRI study. *Neuroimage*, *40*, 1902-1911.

Craig, A. D. (2002). How do you feel? Interoception: the sense of physiological condition of the body. *Nature Reviews Neuroscience*, *3*, 655-666.

Craig, A. D. (2009). How do you feel – now? The anterior insula and human awareness. *Nature Reviews Neuroscience*, *10*, 59-70.

Craig, A. D, Reiman, E. M., Evans, A., & Bushnell, M. C. I. (1996). Functional imaging of an illusion of pain. *Nature*, *384*, 258-260.

Craig, A. D., Chen, K., Bandy, D., & Reiman, E. M. (2000). Thermosensory activation of insular cortex. *Nature Neuroscience*, 3, 184–190.

Cutting, J. (1978). Study of anosognosia. *Journal of Neurology, Neurosurgery, and Psychiatry*, 41, 548-555.

Damasio, A. R., Grabowski, T. J., Bechara, A., Damasio, H., Ponto, L. L. B., Parvizi, J., & Hichwa, R. D. (2000). Subcortical and cortical brain activity during the feeling of self-generated emotions. *Nature Neuroscience*, 3, 1049–1056.

Devue, C., Collette, F., Balteau, E., Degueldre, C., Luxen, A., Maquet, P., & Brédart, S. (2007). Here I am: the cortical correlates of visual self-recognition. *Brain Research*, 1143, 169-182.

Dieterich, M., & Brandt, T. (2008). Functional brain imaging of peripheral and central vestibular disorders. *Brain*, 131, 2538-2552.

Dronkers, N. F. (1996). A new brain region for coordinating speech articulation. *Nature*, 384, 159-161.

Ehrsson, H. H., Spence, C., & Passingham, R. E. (2004). That's my hand! Activity in premotor cortex reflects feeling of ownership of a limb. *Science*, 305, 875-877.

Ehrsson, H. H., Holmes, N. P., & Passingham, R. E. (2005). Touching a rubber hand: feeling of body ownership is associated with activity in multisensory brain areas. *Journal of Neuroscience*, 25, 10564-10573.

Ehrsson, H. H., Wiech, K., Weiskopf, N., Dolan, R. J., & Passingham, R. E. (2007). Threatening a rubber hand that you feel is yours elicits a cortical anxiety response. *Proceedings of the National Academy of Sciences of the USA*, 104, 9828-9833.

Ellis, S., & Small, M. (1997). Localisation in denial of hemiplegia after acute stroke. *Stroke*, 28, 67-71.

Emri, M., Kisely, M., Lengyel, Z., Balkay, L., Márián, T., Mikó, L., Berényi, E., Sziklai, I., Trón, L., & Tóth, A. (2003). Cortical projection of peripheral vestibular signaling. *Journal of Neurophysiology*, *89*, 2639-2646.

Evyapan, D., & Kumral, E. (1999). Pontine anosognosia for hemiplegia. *Neurology*, *53*, 647-649.

Farrell, M. J., Egan, G. F., Zamarripa, F., Shade, R., Blair-West, J., Fox, P., & Denton, D. A. (2006). Unique, common, and interacting cortical correlates of thirst and pain. *Proceedings of the National Academy of Sciences of the USA*, *103*, 2416-2421.

Farrer, C., Franck, N., Georgieff, N., Frith, C. D., Decety, J., & Jeannerod, M. (2003). Modulating the experience of agency: a positron emission tomography study. *Neuroimage*, *18*, 324-333.

Farrer, C., Franck, N., Frith, C. D., Decety, J., Georgieff, N., d'Amato, T., & Jeannerod, M. (2004). Neural correlates of action attribution in schizophrenia. *Psychiatry Research*, *131*, 31-44.

Faurion, A., Cerf, B., Le Bihan, D., & Pillias, A.-M. (1998). fMRI study of taste cortical areas in humans. *Annals of the New York Academy of Sciences*, *855*, 535-545.

Feinberg, T. E., Roane, D. M., & Ali, J. (2000). Illusory limb movements in anosognosia for hemiplegia. *Journal of Neurology, Neurosurgery, and Psychiatry*, *68*, 511-513.

Fiol, M. E., Leppick, I. E., Mireles, R., & Maxwell, R. (1988). Ictus emeticus and the insular cortex. *Epilepsy Research*, *2*, 127-131.

Flynn, F. G., Benson, D. F., & Ardila, A. (1999). Anatomy of the insula – functional and clinical correlates. *Aphasiology*, *13*, 55-78.

Fotopoulou, A., Tsakiris, M., Haggard, P., Vagopoulou, A., Rudd, A., & Kopelman, M. (2008). The role of motor intention in motor awareness: an experimental study on anosognosia for hemiplegia. *Brain*, *131*, 3432-3442

Frith, C. D., Blakemore, S. J., & Wolpert, D. M. (2000). Abnormalities in the awareness and control of action. *Philosophical Transactions of the Royal Society B Biological Sciences*, *355*, 1771-1788.

Frot, M., & Mauguière, F. (2003). Dual representation of pain in the operculo-insular cortex in humans. *Brain*, *126*, 438-450.

Gallagher, S. (2000). Philosophical conceptions of the self: implications for cognitive science. *Trends in Cognitive Sciences*, *4*, 14–21.

Ghika-Schmid, F., van Melle, G., Guex, P., & Bogousslavsky, J. (1999). Subjective experience and behavior in acute stroke: the Lausanne Emotion in Acute Stroke Study. *Neurology*, *52*, 22-28.

Griffiths, D., Tadic, S. D., Schaefer, W., & Resnick, N. M. (2007). Cerebral control of the bladder in normal and urge-incontinent women. *Neuroimage*, *37*, 1-7.

Haggard, P. (2005). Conscious intention and motor cognition. *Trends in Cognitive Sciences*, *9*, 290–295.

Hartman-Maeir, A., Soroker, N., & Katz, N. (2001). Anosognosia for hemiplegia in stroke rehabilitation. *Neurorehabilitation and Neural Repair*, *15*, 213-22.

Heilman, K. M. (1991). Anosognosia: possible neuropsychological mechanisms. In G. P. Prigatano & D. L. Schacter (Eds.), *Awareness of deficit after brain injury* (pp. 53-62). New York: Oxford University Press.

Heilman, K. M., Watson, R. T., Valenstein, E., & Damasio, A. R. (1983). Localization of lesions in neglect. In A. Kertesz (Ed.), *Localization in Neuropsychology* (pp. 471-492). New York: Academic Press.

Hier, D. B., Mondlock, J., & Caplan, L. R. (1983). Recovery of behavioral abnormalities after right hemisphere stroke. *Neurology*, *33*, 345-350.

Humbert, I. A., & Robbins, J. (2007). Normal swallowing and functional magnetic resonance imaging: a systematic review. *Dysphagia*, *22*, 266-275.

Husain, M., & Kennard, C. (1996). Visual neglect associated with frontal lobe infarction. *Journal of Neurology*, *243*, 652-657.

Jehkonen, M., Ahonen, J.-P., Dastidar, P., Laippala, P., & Vilkki, J. (2000). Unawareness of deficit after right hemisphere stroke: double-dissociations of anosognosia. *Acta Neurologica Scandinavica*, *102*, 378-384.

Karnath, H.-O., Ferber, S., & Himmelbach, M. (2001). Spatial awareness is a function of the temporal not the posterior parietal lobe. *Nature*, *411*, 950-953.

Karnath, H.-O., Fruhmann Berger, M., Küker, W., & Rorden, C. (2004). The anatomy of spatial neglect based on voxelwise statistical analysis: a study of 140 patients. *Cerebral Cortex*, *14*, 1164-1172.

Karnath, H.-O., Baier, B. & Nägele, T. (2005). Awareness of the functioning of one's own limbs mediated by the insular cortex? *Journal of Neuroscience*, *25*, 7134-7138.

Kimmerly, D. S., O'Leary, D. D., Menon, R. S., Gati, J. S., & Shoemaker, J. K. (2005). Cortical regions associated with autonomic cardiovascular regulation during lower body negative pressure in humans. *Journal of Physiology*, *569*, 331-345.

Kong, J., White, N. S., Kwong, K. K., Vangel, M. G., Rosman, I. S., Gracely, R. H., & Gollub, R. L. (2006). Using fMRI to dissociate sensory encoding from cognitive evaluation of heat pain intensity. *Human Brain Mapping*, *27*, 715-721.

Levine, D. N., Calvanio, R., & Rinn, W.E. (1991). The pathogenesis of anosognosia for hemiplegia. *Neurology*, *41*, 1770-1781.

Maeshima, S., Dohi, N., Funahashi, K., Nakai, K., Itakura, T., & Komai, N. (1997). Rehabilitation of patients with anosognosia for hemiplegia due to intracerebral hemorrhage. *Brain Injury, 11*, 691-697.

Maihöfner, C., Kaltenhäuser, M., Neundörfer, B., & Lang, E. (2002). Temporo-spatial analysis of cortical activation by phasic innocuous and noxious cold stimuli – a magnetoencephalographic study. *Pain, 100*, 281-290.

Marcel, A., Tegnér, E., & Nimmo-Smith, I. (2004). Anosognosia for plegia: specificity, extension, partiality and disunity of bodily unawareness. *Cortex, 40*, 19-40.

McGlynn, S. M., & Schacter, D. L. (1989). Unawareness of deficits in neuropsychological syndromes. *Journal of Clinical and Experimental Neuropsychology, 11*, 143-205.

Meador, K. J., Loring, D. W., Feinberg, T. E., Lee, G. P., & Nichols, M. E. (2000). Anosognosia and asomatognosia during intracarotid amobarbital inactivation. *Neurology, 55*, 816-820.

Mesulam, M. M., & Mufson, E. J. (1985). The insula of reil in man and monkey. Architectonics, connectivity, and function. In A. Peters & E. G. Jones (Eds.), *Cerebral Cortex* (pp. 179-226). New York: Plenum Press.

Moseley, G. L., Olthof, N., Venema, A., Don, S., Wijers, M., Gallace, A., & Spence, C. (2008). Psychologically induced cooling of a specific body part caused by the illusory ownership of an artificial counterpart. *Proceedings of the National Academy of Sciences of the USA, 105*, 13169-13173.

Naidich, T. P., Kang, E., Fatterpekar, G. M., Delman, B. N., Gultekin, S. H., Wolfe, D., Ortiz, O., Yousry, I., Weismann, M., & Yousry, T. A. (2004). The insula: anatomic study and MR imaging display at 1.5 T. *American Journal of Neuroradiology, 25*, 222-232.

Naqvi, N. H., Rudrauf, D., Damasio, H., & Bechara, A. (2007). Damage to the insula disrupts addiction to cigarette smoking. *Science*, *315*, 531-534.

Nathanson, M., Bergman, P., & Gordon, G. (1952). Denial of illness. Its occurrence in one hundred consecutive cases of hemiplegia. *Archives of Neurology and Psychiatry*, *68*, 380-387.

Ogawa, H., Wakita, M., Hasegawa, K., Kobayakawa, T., Sakai, N., Hirai, T., Yamashita, Y., & Saito, S. (2005). Functional MRI detection of activation in the primary gustatory cortices in humans. *Chemical Senses*, *30*, 583-592.

Orfei, M. D., Robinson, R. G., Prigatano, G. P., Starkstein, S., Rüsçh, N., Bria, P., Caltagirone, C., & Spalletta, G. (2007). Anosognosia for hemiplegia after stroke is a multifaceted phenomenon: a systematic review of the literature. *Brain*, *130*, 3075-3090.

Paulus, M.P., & Stein, M. B. (2006). An insular view of anxiety. *Biological Psychiatry*, *60*, 383-387.

Phillips, M. L., Young, A. W., Senior, C., Brammer, M., Andrew, C., Calder, A. J., Bullmore, E. T., Perrett, D. I., Rowland, D., Williams, S. C. R., Gray, J. A., & David, A. S. (1997). A specific neural substrate for perceiving facial expressions of disgust. *Nature*, *389*, 495-498.

Pia, L., Neppi-Modona, M., Ricci, R., & Berti, A. (2004). The anatomy of anosognosia for hemiplegia: a meta-analysis. *Cortex*, *40*, 367-377.

Rhoton, A. L. (2007). The Cerebrum. Anatomy. *Neurosurgery*, *61* (Suppl 1), 37-118.

Rode, G., Charles, N., Perenin, M.-T., Vighetto, A., Trillet, M., & Aimard, G. (1992). Partial remission of hemiplegia and somatoparaphrenia through vestibular stimulation in a case of unilateral neglect. *Cortex*, *28*, 203-208.

Rorden, C., & Karnath, H.-O. (2004). Using human brain lesions to infer function: a relic from a past era in the fMRI age? *Nature Reviews Neuroscience*, *5*, 813-819.

Rorden, C., Karnath, H.-O., & Bonilha, L. (2007). Improving lesion-symptom mapping. *Journal of Cognitive Neuroscience*, *19*, 1081-1088.

Rorden, C., Fridriksson, J., & Karnath, H.-O. (2009). An evaluation of traditional and novel tools for lesion behavior mapping. *Neuroimage*, *44*, 1355-1362.

Schneider, R. C., Calhoun, H. D., & Kooi, K. A. (1971). Circling and rotational automatisms in patients with frontotemporal cortical and subcortical lesions. *Journal of Neurosurgery*, *35*, 554-563.

Schneider, R. J., Friedman, D. P., & Mishkin, M. (1993). A modality-specific somatosensory area within the insula of the rhesus monkey. *Brain Research*, *621*, 116 –120.

Schreckenberger, M., Siessmeier, T., Viertmann, A., Landvogt, C., Buchholz, H. G., Rolke, R., Treede, R. D., Bartenstein, P., & Birklein, F. (2005). The unpleasantness of tonic pain is encoded by the insular cortex. *Neurology*, *64*, 1175-1183.

Showers, M. J. C., & Lauer, E. W. (1961). Somatovisceral motor patterns in the insula. *Journal of Comparative Neurology*, *117*, 107-115.

Spinazzola, L., Pia, L., Folegatti, A., Marchetti, C., & Berti, A. (2008). Modular structures of awareness for sensorimotor disorders: evidence from anosognosia for hemiplegia and anosognosia for hemianaesthesia. *Neuropsychology*, *46*, 915-926.

Starkstein, S. E., Fedoroff, J. P., Price, T. R., Leiguarda, R., & Robinson, R. G. (1992). Anosognosia in patients with cerebrovascular lesions. *Stroke*, *23*, 1446-1453.

Stein, M. B., Simmons, A. N., Feinstein, J. S., & Paulus, M. P. (2007). Increased amygdala and insula activation during emotion processing in anxiety-prone subjects. *American Journal of Psychiatry*, *164*, 318-327.

Stone, S. P., Halligan, P. W., & Greenwood, R. J. (1993). The incidence of neglect phenomena and related disorders in patients with an acute right or left hemisphere stroke. *Age and Aging, 22*, 46-52.

Sugar, O., Chusid, J. G., & French, J. D. (1948). A second motor cortex in the monkey (*Macaca mulatta*). *Journal of Neuropathology & Experimental Neurology, 7*, 182-189.

Tsakiris, M., & Haggard, P. (2005). The rubber hand illusion revisited: visuotactile integration and self-attribution. *Journal of Experimental Psychology: Human Perception and Performance, 31*, 80–91.

Tsakiris, A., Hesse, M. D., Boy, C., Haggard, P., & Fink, G. R. (2007a). Neural signatures of body ownership: a sensory network for bodily self-consciousness. *Cerebral Cortex, 17*, 2235-2244.

Tsakiris, M., Schütz-Bosbach, S., & Gallagher, S. (2007b). On agency and body-ownership: phenomenological and neurocognitive reflections. *Consciousness and Cognition, 16*, 645–660.

Türe, U., Yaşargil, D. C., Al-Mefty, O., & Yaşargil, M. G. (1999). Topographic anatomy of the insular region. *Journal of Neurosurgery, 90*, 720-733.

Vallar, G., & Perani, D. (1986). The anatomy of unilateral neglect after right-hemisphere stroke lesions. A clinical/CT-scan correlation study in man. *Neuropsychologia, 24*, 609-622.

Vallar, G., Bottini, G., & Sterzi, R. (2003). Anosognosia for left-sided motor and sensory deficits, motor neglect, and sensory hemiattention: is there a relationship? In C. Prablanc, D. Pélisson, & Y. Rossetti Y (Eds.), *Progress in Brain Research, Vol. 142* (pp. 289-301). Amsterdam: Elsevier Science.

Weinstein, E. A., & Kahn, R. L. (1955). *Denial of Illness: Symbolic and Physiological Aspects*. Springfield, Ill.: Charles C. Thomas.

Wolpert, D. M. (1997). Computational approaches to motor control. *Trends in Cognitive Sciences*, 1, 209–216.

Acknowledgements

This work was supported by the Bundesministerium für Bildung und Forschung (BMBF-Verbundprojekt "Räumliche Orientierung" 01GW0641) and the Deutsche Forschungsgemeinschaft (SFB 550-A4). We are grateful to Bud Craig, Aikaterini Fotopoulou, George Prigatano, and Patrik Vuilleumier for their insightful comments and discussion. We also would like to thank Andrea Starmans for figure 3 illustrating the rubber hand illusion as well as Jennifer Gray for her help with the English language.

Legends

Figure 1.

Percentage of additional disturbance of sensing limb ownership (DSO) as well as other abnormal attitudes towards and/or perceptions of the paretic/plegic limb(s) found in a continuously admitted sample of patients with anosognosia for hemiparesis/-plegia (AHP). Asomatognosia and somatoparaphrenia have the common characteristic that the subjects experience a disturbed ownership of their contralateral limb(s). Both misbeliefs thus were combined and illustrated as "disturbed sensation of limb ownership (DSO)". All but one (=92%) of the patients with AHP also showed DSO. The finding argued for a tight link between our sense of agency and our sense of limb ownership. (from Baier & Karnath, 2008).

Figure 2.

(A) Overlay plot of the subtracted superimposed lesions of a group of right brain damaged patients with AHP minus a group of patients without AHP (control group). Wh. mat., white matter (from Karnath et al., 2005). **(B)** Overlay plot of the subtracted superimposed lesions of a patient group showing a disturbed sense of limb ownership (DSO) and AHP minus a control group without the disorder (from Baier & Karnath, 2008). In each panel, the percentage of overlapping lesions of the anosognosia patients after subtraction of controls is illustrated by 5 colors coding increasing frequencies from dark red (difference = 1% to 20 %) to white-yellow (difference = 81% to 100%). Each color represents 20% increments. The colors from dark blue (difference = -1% to -20%) to light blue (difference = -81% to -100%) indicate regions damaged more frequently in control patients. MNI z-coordinates of each transverse slice are given. In concordance, the two independent patient samples and analyses (panels A and B) revealed that the right insula is commonly damaged in patients with AHP and DSO but is significantly less affected in patients without these disorders.

Figure 3.

The rubber hand illusion. In the illusion, the subjects observe a facsimile of a human hand (the rubber hand) while their own hand is hidden from view (A). Synchronously touching of the subject's hand and of the artificial hand with a probe leads to the illusion as if the rubber hand belongs to one's own body (B).

Table 1.

Clinical scale to test for a disturbed belief about the functioning of own limbs (sense of agency). It represents a modified version of the anosognosia scale suggested by Bisiach and co-workers (1986). (from Baier & Karnath, 2005).

<p><u>No Anosognosia</u></p> <ul style="list-style-type: none">• The disorder is spontaneously reported or mentioned by the patient following a general question about his/her complaints <i>(former grade 0 by Bisiach et al. 1986)</i>• The disorder is reported only following a specific question about the strength of the patient's limbs <i>(former grade 1 by Bisiach et al. 1986)</i>
<p>Anosognosia – Grade I</p> <ul style="list-style-type: none">• The disorder is acknowledged only after demonstrations through routine techniques of neurological examination <i>(former grade 2 by Bisiach et al. 1986)</i>
<p>Anosognosia – Grade II</p> <ul style="list-style-type: none">• No acknowledgement of the disorder is obtained <i>(former grade 3 by Bisiach et al. 1986)</i>

Table 2.

Questionnaire to test for a disturbed sense of limb ownership (DSO) as well as for other abnormal attitudes towards and/or perceptions of paretic/plegic limbs. (from Baier & Karnath, 2008).

Disturbed sense of limb ownership (DSO)	Is this your arm/leg? (combined with pointing or elevating the arm/leg) [aspect: asomatognosia]
	To whom belongs this arm/leg? (combined with pointing or elevating the arm/leg) [aspect: somatoparaphrenia]

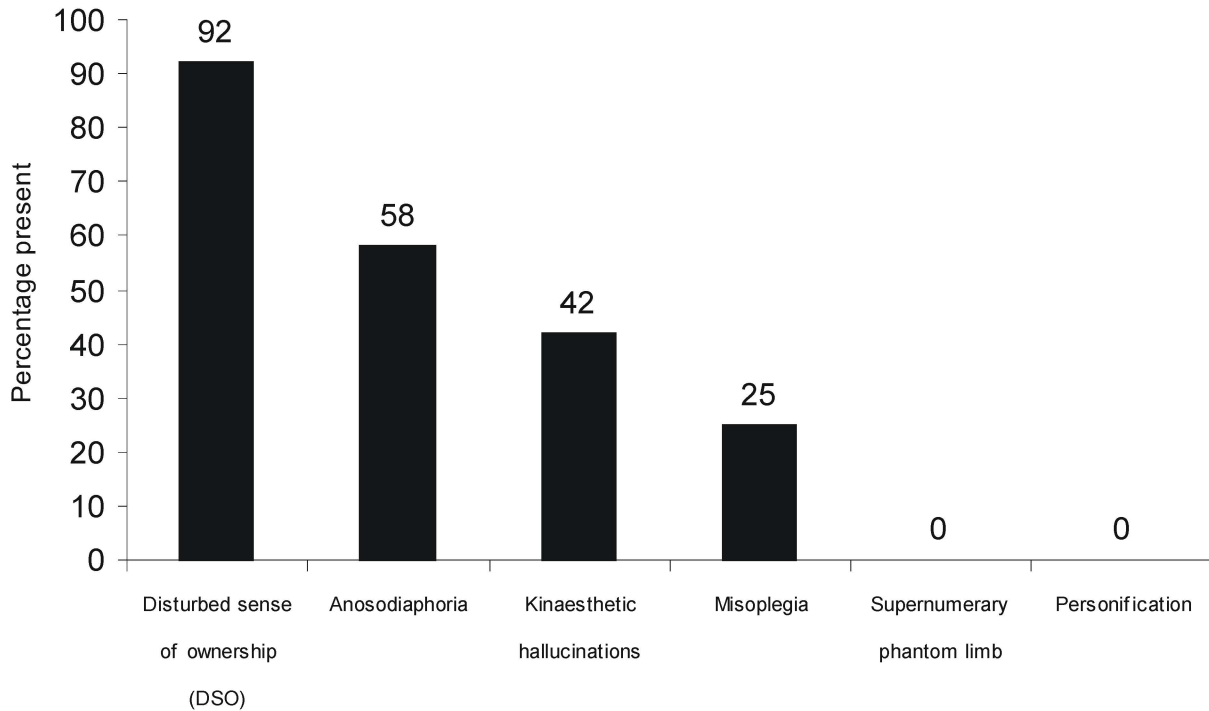
Anosodiaphoria	Does the weakness of your arm/leg represent a strong impairment or just a minor issue, which is not important to you?
-----------------------	---

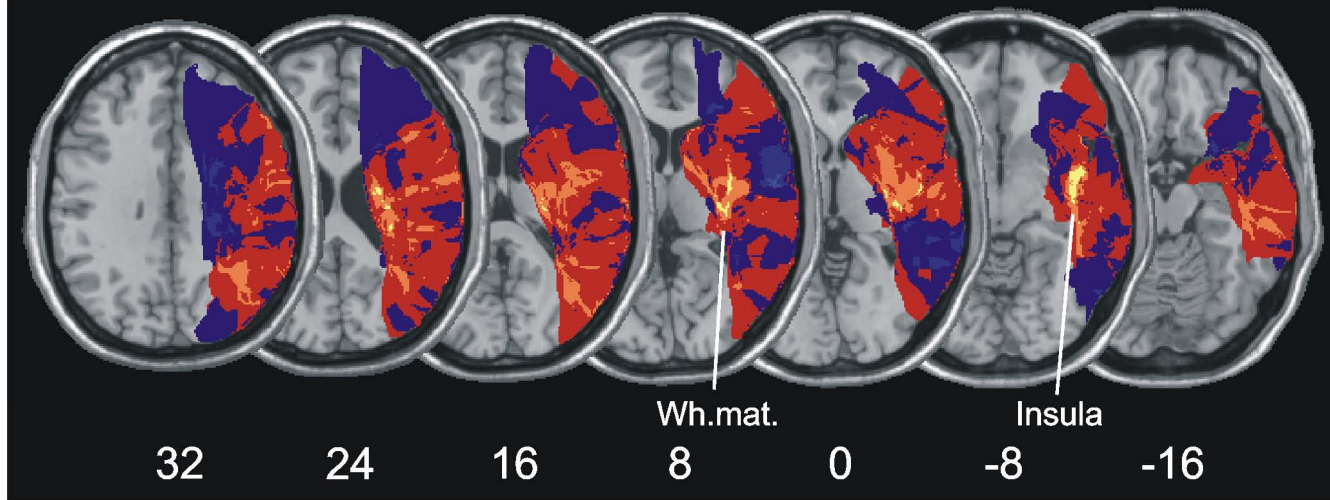
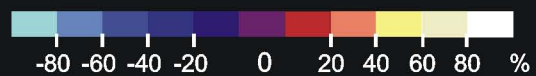Misoplegia	Do you have any emotions for your arm/leg? Do you hate or deny your arm/leg?
-------------------	--

Personification	Does your arm/leg have a name? Have you ever given your leg/arm a name?
------------------------	---

Kinesthetic hallucinations	Have you ever had the impression that your arm/leg moves without your own will, i.e. without you having moved it/having initiated the movement? Does your arm/leg move as if controlled by an invisible hand?
-----------------------------------	---

Supernumerary phantom limb	How many arms/legs do you have? Do you have the feeling that you have another arm/leg beyond the two arms/legs that you have since birth?
-----------------------------------	---



A**Anosognosia vs. Controls****B****DSO vs. Controls**